



Magnetic Resonance Imaging in the Preoperative T Staging of Gastric Cancer (A Critical Appraisal)

**Syed Sajad Ahmad^{1*}, Irfan Robbani¹, Sheikh Riaz Rasool¹,
Syed Besina Yaseen², Rouf Ahmad Wani³, Abdul Wahid Mir³
and Tabasum Mushtaq⁴**

¹Department of Radiology, Sher-i-Kashmir Institute of Medical Sciences Srinagar, Kashmir, India.

²Department of Pathology, Sher-i-Kashmir Institute of Medical Science Srinagar, Kashmir, India.

³Department of General Surgery, Sher-i-Kashmir Institute of Medical Sciences Srinagar, Kashmir, India.

⁴Department of Statistics, Sher-e-Kashmir University of Agricultural Sciences and Technology, Kashmir, India.

Authors' contributions

This work was carried out in collaboration among all authors. Author SSA designed the study, wrote the protocol, managed the data collection and wrote the first draft of the manuscript. Author IR conceived the idea and supervised the study. Authors SRR, SBY, RAW and AWM managed the literature searches. Author TM performed the statistical analysis and interpreted the findings. All authors read and approved the final manuscript.

Article Information

DOI: 10.9734/IJTDH/2020/v41i630285

Editor(s):

(1) Dr. Nasser Mousa, Mansoura University, Egypt.

(2) Dr. Zhiheng Zhou, Massachusetts General Hospital, Harvard Medical School, USA and Guangzhou University, China.

Reviewers:

(1) Leonardo David Villacrés Montesdeoca Quito, Universidad Central del Ecuador, Ecuador.

(2) Roshini Sathiaselalan, University of Oklahoma Health Sciences Center, United States of America.

(3) Ritika Gupta, College of Dental Sciences and Hospital, India.

Complete Peer review History: <http://www.sdiarticle4.com/review-history/58432>

Original Research Article

Received 15 April 2020

Accepted 20 June 2020

Published 24 June 2020

ABSTRACT

Background: Gastric cancer accounts for many cancer-related deaths, is one of the top leading cause of cancer-associated mortality. Tumor staging and classification depends upon histological, immune histochemical tests along with the radiological imaging. In the preoperative T staging of gastric cancer, Magnetic Resonance Imaging (MRI) has become principal attention in recent years. **Aim:** Evaluating the accuracy of MRI in the preoperative T staging of gastric cancer vis-a-vis post-operative pathological staging.

*Corresponding author: Email: syedsajadahmad626@gmail.com;

Methods: A total of 37 patients were initially taken in our study, out of which 13 patients were excluded as they underwent neo adjuvant chemoradiotherapy for the down staging of the tumor. The 24 patients became the sample size of our study and their magnetic resonance imaging (MRI) T stage was correlated with pathological T-stage.

Results: The diagnostic accuracy of T₁ stage by MRI was 87.5%, with 94.7% specificity and 60% sensitivity (n=24, κ -value = 0.58; P-value<0.05). The diagnostic accuracy of T₂ stage by MRI was 87.5%, with 88.2% specificity and 85.7% sensitivity (n=24, κ -value= 0.69; P-value<0.05). The diagnostic accuracy of T₃ stage by MRI was 91.7% with 93.3% specificity and 88.9% sensitivity (n=24, κ -value= 0.82; P-value<0.05). The diagnostic accuracy of T₄ stage by MRI was 95.8%, with 100% specificity and 75% sensitivity (n=24, κ -value= 0.80; P-value<0.05).

Conclusion: Because of high accuracy and specificity in determining the depth of invasion of gastric cancer, MRI proves to be an invaluable diagnostic tool in the preoperative T staging of gastric cancer and therefore is very useful in sidestepping unnecessary surgery by supervising the selection of treatment decisions.

Keywords: Magnetic resonance imaging; gastric cancer; tumor stage.

1. INTRODUCTION

Gastric carcinoma (GC) ranks fourth popular well-known malignancy and another top cause of cancer-associated deaths with approximately 20% of five years survival rate around the world [1]. In the south Asian countries, especially Japan, The Republic of Korea, and China this disease is more predominant [2,3]. The area and the separation of the gastric adenocarcinoma differ as do the degrees of disease development, at which patients present when detected. As GC is among the chief killers, it is imperative that patients are checked and the diagnosis is set up as ahead of schedule as could reasonably be expected and treatment started right away. The locoregional spread of the tumor and distant metastasis determines the treatment options. Staging of tumor and classification frequently calls for a combination of immunohistochemical tests with radiological imaging [4]. The lesion detection and the preoperative staging of gastric cancer can be done by different imaging modalities liable on the complexity of the clinical settings or stage of the disease. These include "double-contrast barium radiography", "endoscopic ultrasound (EUS)", "computed tomography (CT)", "magnetic resonance imaging (MRI)", "positron emission tomography (PET)", "somatostatin receptor scintigraphy (SRS)" [5-12]. Furthermore, to detect and stage gastric cancer, "these imaging techniques are also beneficial in detecting other lesions neuroendocrine tumors" [13], "stromal tumors"⁴ and "lipomas" [14].

In addition to MRI's technical versatility for sequence selection and modification, and without ionizing radiation, it is a robust and excellent imaging modality with high soft-tissue contrast

resolution. In previous years, MRI was unsuitable for the staging of GC due to the long acquisition time and motion artifacts. With the development of fast imaging sequences and techniques of reducing motion-related MRI artifacts these limitations have recently been partially overcome [15]. These improvements include breath-hold fast imaging techniques, placement of abdominal binders, administration of anti-peristaltic agents, and the use of phased array coils. The depiction of gastric wall layers has been performed by many in vitro studies using 1 - 4.7- T MR systems and therefore, technically permits the evaluation of the local tumor stage of gastric cancer. Recently, there has been much research using MRI to assess the pre-operative staging of Gastric carcinomas.

"The accuracy of Tumor, Node Metastasis (TNM) classification in staging gastric cancer has gradually improved with the utilization and development of magnetic resonance imaging (MRI) and exhibited its superiority" [5]. Matsushita *et.al* previously considered that "the spoiled Gradient recalled echo technique was able to display signal layers that were lower than stomach and omentum signal layers and that the T₃ stage of extra-serous infiltration was likely to be expressed as the disappearance of the band or hyperintense lesions that entered this band" [16]. Hence nowadays MR imaging in preoperative T staging of gastric cancer is becoming a predominant focus" [16]. In light of recent exciting work on the role of MRI in gastric cancer, we have undertaken this study which attempts to evaluate the efficiency of MRI as a diagnostic tool for pre-operatively evaluating the stage of gastric vis-a-vis post-operative pathological staging.

1.1 Objectives

The study was done to evaluate the diagnostic accuracy of magnetic resonance imaging in the preoperative evaluation of tumor stage (T-stage) of gastric cancer and correlate the MRI T stage with the corresponding pathological T stage.

2. MATERIALS AND METHODS

2.1 Study Population

The study was conducted in the Department of Radiodiagnosis and Imaging, Sher-i-Kashmir Institute of Medical Sciences, Srinagar in collaboration with the department of Surgery and the department of Pathology commencing from June 2017 to July 2019. Newly diagnosed and histologically (after endoscopic biopsy) proven gastric cancer patients were included in the study. Thirty-seven patients (twenty-six men, eleven women; mean age 54 years) were enrolled with the diagnosis of endoscopic gastric carcinoma. Following criteria was opted for excluding the patients:

- (1) Patients that were treated pre-surgically with chemotherapy or radiotherapy because of which down staging of tumor occurs.
- (2) Patients in whom MRI is otherwise contraindicated (e.g. metallic prosthesis, non-MR compatible pacemakers).
- (3) Patients with metastatic disease as they cannot have a curable surgical resection.
- (4) Claustrophobia
- (5) History of contrast hypersensitivity

2.2 Data Acquisition

Within 9 days after endoscopy, all patients underwent MR imaging. Twenty patients (54.05%) underwent total or partial gastrectomy via laparotomy. Within one week from pre-operative staging. Before resection thirteen patients (35.14%) were listed for neoadjuvant chemotherapy, and owing to the local extent of disease, four patients (10.81%) underwent palliative surgery. All patients with extranodal metastases (brain, liver, lungs,) and who received neoadjuvant chemotherapy were excluded from the study. MRI studies were performed using 1.5T MR system ("Magnetom Avanto" [17], "Siemens Medical systems" [17], "Erlangen" [17], Germany) after patient preparation that included patient fasting for six

hours, gastric distention by drinking water (500 ml) 15-30 minutes before the investigation and administration of 10 ml of "intramuscular hyoscine butyl-bromide (Buscopan) as an anti-peristaltic agent" [17]. Before the patient lying on the examination table additional 500 ml of water was administered. In the prone position, patients with lesions of the cardinal region were imaged. With a 1.5-T scanner (gradient strength 45 mT/m, slew S rate 346 T/m/s, rise time 400 ms) MR examinations were made. In the axial and coronal planes, pre-contrast images were obtained with true fast imaging with steady-state precession (true FISP), T₂-weighted turbo spin-echo (TSE), Volumetric interpolated breath-hold examination (VIBE) and Half-Fourier- (HASTE) sequences (Table 1, Fig. 1, Fig. 2).

"After the intravenous administration of 20 mg gadodiamide (Omniscan) images were acquired in the arterial and venous phases using T₁-weighted 3D volumetric interpolated breath-hold examination (VIBE) sequences (Table 1). MR imaging studies were evaluated preoperatively. The T parameter was staged according to the Tumor Node Metastasis (TNM) classification established by the American Joint Committee on Cancer and by the International Union against Cancer" [17]. Following classification has been opted for progression of tumor invasion on MR images:

- "T₁: Slight enhancement and focal thickening of the inner layer of the gastric wall" [17].
- "T₂: Diffuse enhancement and thickening of the entire gastric wall without extramural spread" [17]
- "T₃: Diffuse enhancement and thickening of the entire gastric wall, with irregularities and invasion of the perivisceral fat" [17].
- "T₄: Infiltration of adjacent organs, including vascular structures" [17].

2.3 Statistical Analysis

MRI diagnosis for the T stage of 24 patients with gastric cancer was compared with the post-operative pathological diagnosis. κ values were used as the index to measure the degree of consistency. If the κ value was ≥ 0.75 , this indicated that a very satisfactory degree of consistency had been obtained. If the κ value was < 0.4 , this indicated that the desired consistency level was insufficient. κ values between 0.4-0.75 meant fair to good reliability.

The present study also examined k values using the Mann-Whitney U test. $P < 0.05$ was considered to indicate a statistically significant difference. All statistical analyses were performed using SPSS 25.0 software (SPSS, Inc., Chicago, IL, USA).

Table 1. Protocol for magnetic resonance imaging (MRI) Scan

MRI sequence	True fast imaging with steady state precession (TrueFISP)	T ₂ - Turbo spin echo (T ₂ -TSE)	Volumetric interpolated breath-hold examination (VIBE)	Half-Fourier acquired single-shot turbo spin echo (HASTE)
Repetition time(ms)	3.8	4000	5.8	9000
Echo time(ms)	1.9	101	2.3	92
Thickness(mm)	3	3	3	5
Flip angle (°)	73	150	10	150
Matrix size(pixel)	448×448	448×448	448×448	448×448
iPAT	×2	×2	×2	×2

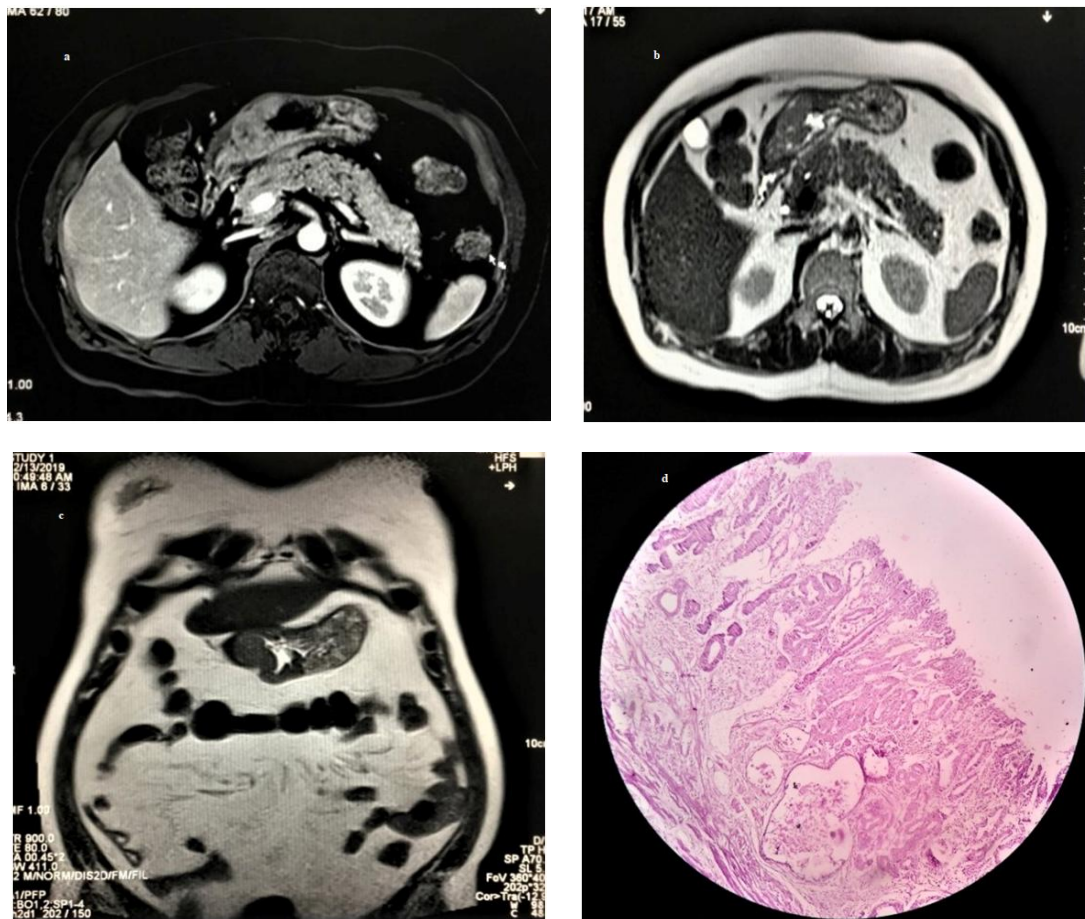
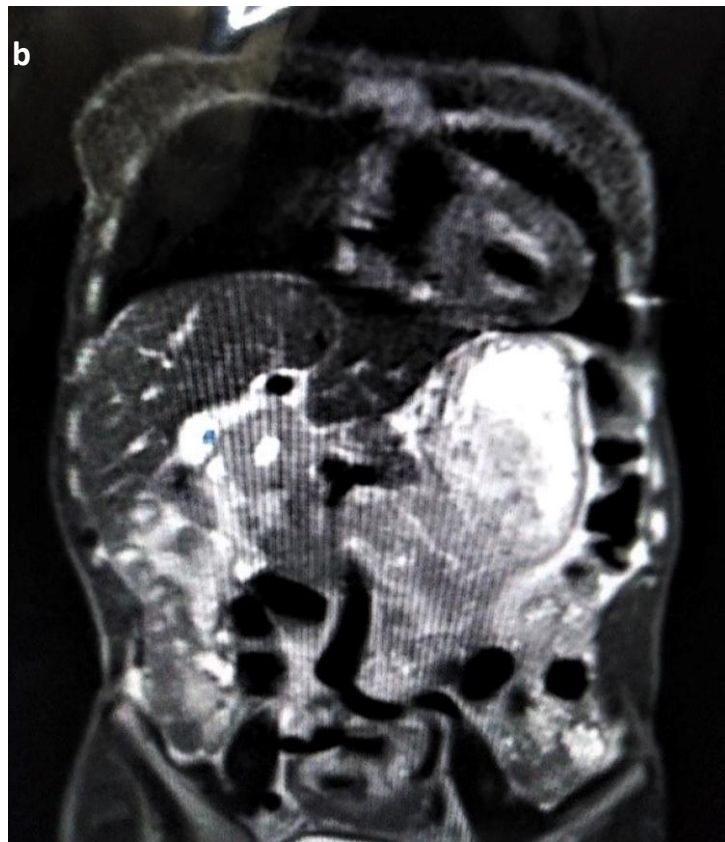
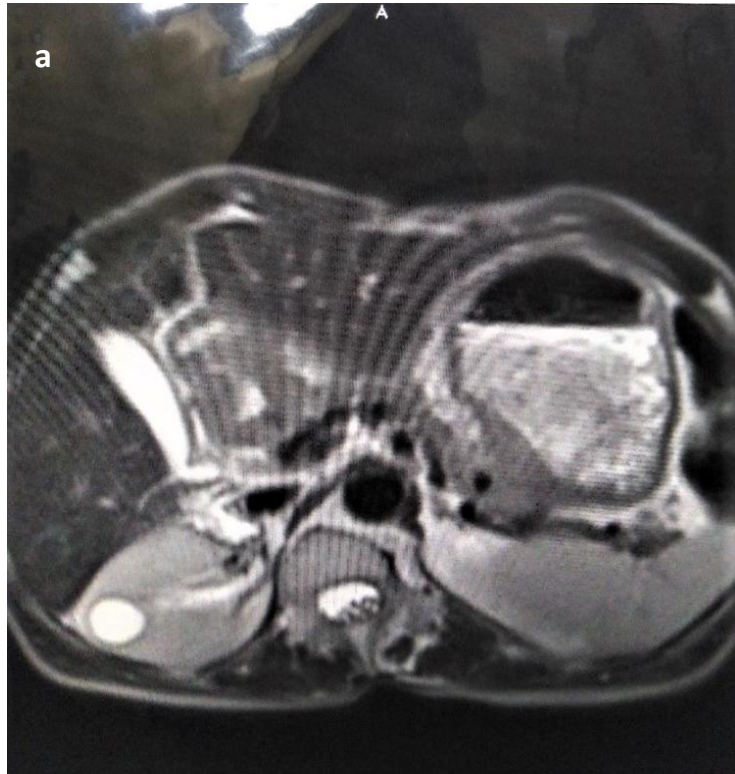
Fig. 1. Post contrast VIBE (a) and T₂ HASTE (b, c) sequences showing full-thickness lesion of the gastric antrum without extension to the perivisceral fat tissue (stage T₂). In. Infiltration of the peri-gastric fat tissue can be excluded with MRI technique. Findings were consistent with microscopic findings as shown in T₄ (10X) microscopic specimen (d) showing tumor cells within muscularis propria



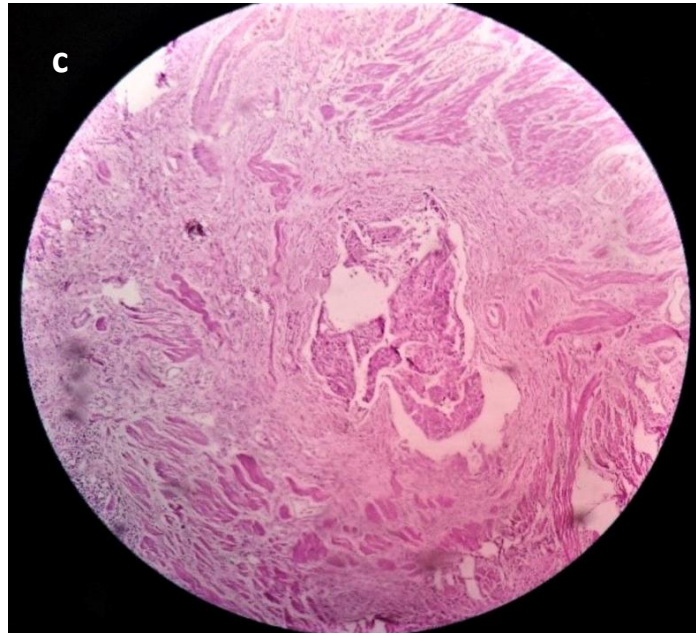


Fig. 2. T₂ HASTE Axial and Coronal images (a, b) showing circumferential thickening involving pylorus with ill-defined T₂ hypointense serosal layer and mild streakiness of surrounding peri-gastric fat suggestive of T₃ gastric lesion. Microscopic specimen (10X) showing T₃ disease (c)

3. RESULTS

3.1 T₁ Stage Comparison

Three cases of MRI were diagnosed correctly; one case was misdiagnosed and two cases were missed. The diagnostic accuracy of T₁ stage by MRI was 87.5%, with 94.7% specificity and 60% sensitivity [κ -value = 0.58; P-value<0.05; Table 2].

3.2 T₂ Stage Comparison

Six cases of MRI were diagnosed correctly; two cases were misdiagnosed (one case overestimating and one case underestimating) and one case was missed. Due to the unclear appearance of the external edge the underestimated case was diagnosed as the T₃ stage, while the overestimated one case was diagnosed as the T₁ stage, as stronger signals were induced by the thin wall. The diagnostic accuracy of T₂ stage by MRI was 87.5%, with 88.2% specificity and 85.7% sensitivity [κ -value= 0.69; P-value<0.05; Table 2].

3.3 T₃ Stage Comparison

Eight cases of MRI were diagnosed correctly, one case (under-estimating) was misdiagnosed

and one case was missed. Due to the equivocal expansion of the fat neighbouring the lesion, the underestimated case was diagnosed as the T₄ stage. The diagnostic accuracy of T₃ stage by MRI was 91.7% with 93.3% specificity and 88.9% sensitivity [κ -value= 0.82; P-value<0.05; Table 2].

3.4 T₄ Stage Comparison

Three cases of MRI were diagnosed correctly; one case was missed and no case was misdiagnosed. The diagnostic accuracy of T₄ stage by MRI was 95.8%, with 100% specificity and 75% sensitivity [κ -value= 0.80; P-value<0.05; Table 2].

The above results revealed the statistical significance of the comparison of MRI preoperative T staging of gastric cancer with postoperative pathological observations particularly for the diagnosis of T₃ and T₄ stages. All P-values were<0.001. A fairly satisfactory degree of consistency between the two diagnostic methods was reflected for the T₃ and T₄ stages as their κ -values were >0.75.

4. DISCUSSION

Without a proper picture of the gastric wall layers, accurate difference between T₁, T₂ and T₃ tumors cannot be attained. There is growing

Table 2. Analytical comparison of MRI and Surgical pathological diagnosis of the depth of invasion (T stage) in 24 gastric cancer patients

MRI	Surgical pathology								
	Positive	Negative	Sensitivity% (n)	Specificity % (n)	Positive prediction value, % (n)	Negative prediction value, % (n)	Accuracy % (n)	K	P-value
T ₁			60.0 (3/5)	94.7 (18/19)	75.0 (3/4)	90.0(18/20)	87.5 (21/24)	0.58	<0.001
Positive	3	1							
Negative	2	18							
T ₂			85.7 (6/7)	88.2 (15/17)	75.0 (6/8)	93.8 (15/16)	87.5 (21/24)	0.69	<0.001
Positive	6	2							
Negative	1	15							
T ₃			88.9 (8/9)	93.3 (14/15)	88.9 (8/9)	93.3 (14/15)	91.7 (22/24)	0.82	<0.001
Positive	8	1							
Negative	1	14							
T ₄			75.0 (3/4)	100 (20/20)	100 (3/3)	95.2 (20/21)	95.8 (23/24)	0.80	<0.001
Positive	3	0							
Negative	1	20							

*"P-value: "the possibility of occurrence of an event the size of the reaction" [18],
Sensitivity: "Positive surgical pathology and MRI values)/Total positive surgical pathology value" [18],
Specificity: "Negative surgical pathology and MRI values/Total negative surgical pathology value" [18],
Positive prediction: "Positive surgical pathology and MRI values/Total Positive MRI value" [18],
Negative prediction: "Negative surgical pathology and MRI values/Total Negative MRI value" [18],
Accuracy: "matched MRI and surgical pathology diagnosis/total patients" [18]*

attention in the use of MRI for the staging of gastric carcinoma, but most of the tumor staging doesn't employ the differentiation of gastric wall layers [19-22]. "Limited number of studies is available that use depiction of gastric wall layers as a basis for local tumor staging and lymph node metastasis" [23].

Thirteen patients among the thirty-seven patients enrolled in our study were excluded because they were planned for neoadjuvant chemoradiotherapy. The remaining 24 patients were chosen as the sample size of our study and their MR imaging T stage was correlated with pathological T-stage. Evaluation of MR studies was done by using the pre-contrast sequences (true-FISP, HASTE, and TSE) and post Gadolinium administration (VIBE 3D) sequences. Although the four sequences were seen independently to enable comparison among sequences, T staging was carried out on MR imaging with a combined evaluation. 20 patients out of the 24 underwent total or partial gastrectomy and 4 patients were taken for palliative surgery mostly of the T₄ stage. For histological examination, the surgical specimens were sent to the department of pathology. Analysis by microscopy after haematoxylin-eosin staining of the surgical specimen was done to determine the depth of invasion which was compared with the adjacent normal-appearing gastric wall. In total, four cases of T₁ stage, eight cases of T₂ stage, nine cases of T₃ stage, and three cases of T₄ stage were identified on MR imaging. In total, five cases of T₁, seven cases of T₂, nine cases of T₃ and, four cases of T₄ stage were identified by postoperative pathology. The accuracy of MRI for staging T₁ lesion was 87.5% with a specificity of 94.7% and sensitivity of 60%. In the T₂ stage accuracy of MRI in staging the gastric lesion was 87.5% with a specificity of 88.2% and sensitivity of 85.7%. In T₃ and T₄ stages, the diagnostic accuracy of MRI was highest. The diagnostic accuracy in staging T₃ gastric lesion stood out at 91.7% with a specificity of 93.3% and sensitivity of 88.9%. Finally, the diagnostic accuracy in staging T₄ disease was 95.8% with a specificity of 100% and sensitivity of 75%. From these findings, we conclude that pre-operative MRI tumor (T) stage of gastric cancer correlates well with the corresponding pathological T stage. Hence, MRI is an outstanding diagnostic tool in the preoperative T staging of gastric cancer due to its high accuracy and specificity in determining the depth of invasion of gastric cancer.

5. CONCLUSION

Because of high accuracy and specificity in determining the depth of invasion of gastric cancer, MRI proves to be an invaluable diagnostic tool in the preoperative T staging of gastric cancer and therefore is very useful in sidestepping unnecessary surgery by supervising the selection of treatment decisions.

CONSENT AND ETHICAL APPROVAL

As per university standard guideline, participant consent and ethical approval have been collected and preserved by the authors.

ACKNOWLEDGEMENTS

We thank the Faculty, Department of Pathology & Department of Surgery, Sher-i-Kashmir Institute of Medical Sciences, Kashmir, India for supporting our study.

COMPETING INTERESTS

Authors have declared that no competing interests exist.

REFERENCES

1. Kwee RM, Kwee TC. Imaging in assessing lymph node status in gastric cancer. *Gastric Cancer*. 2009;12:6–22.
2. Moore MA, Manan AA, Chow KY, et al. Cancer epidemiology and control in peninsular and island South-East Asia—past, present and future. *Asian Pacific Journal of Cancer Prevention*. 2010;11:81–98.
3. Kamangar F, Dores GM, Anderson WF. Patterns of cancer incidence, mortality, and prevalence across five continents: Defining priorities to reduce cancer disparities in different geographic regions of the world. *Journal of Clinical Oncology*. 2006;24:2137–50.
4. Mignon F, Julie C, Izzillo R, et al. Imaging features of gastric stromal tumors: Radiologic-pathologic correlation. Report of 4 cases. *Journal of Radiology*. 2000; 81:874-81.
5. Bruneton JN, Francois E, Padovani B, et al. Primary tumor staging of gastric and. *European Journal of Radiology*. 1996;6: 140-146.
6. Kluetz P, Villemagne VV, Meltzer C, et al. The case for PET/CT. Experience at the

- University of Pittsburgh. Clinical Positron Imaging. 2000;3:174.
7. Portnoi LM, Kazantseva IA, Stashuk GA, et al. Current X-ray diagnosis of stomach cancer (comparison of radiologic and morphological methods of investigation). Vestn Rentgenol Radiol. 2000;6:19-29.
 8. Portnoi LM, Kazantseva IA, Viatchanin OV, et al. Cancer of the upper stomach: Current problems of its diagnosis. Vestn Rentgenol Radiol. 2003;1:4-22.
 9. Drop A, Zbanska-Klonowska K, Czekajski-Chehab E, et al. The modern methods of gastric imaging. Annales Universitatis Mariae Curie-Sklodowska Med. 2004;59: 373-81.
 10. Cordin J, Lehmann K, Schneider PM. Clinical staging of adenocarcinoma of the esophagogastric junction. Recent Results in Cancer Research. 2010;182:73-83.
 11. Tang L. Staging and response evaluation of gastric cancer: Requirements and resolutions by multidisciplinary treatment. Chinese Journal of Gastrointestinal Surgery. 2015;18:208-12.
 12. Matthews R, Choi M. Clinical utility of positron emission tomography magnetic resonance imaging (PET-MRI) in Gastrointestinal Cancers. Diagnostics (Basel). 2016;6:35.
 13. Zimmer T, Ziegler K, Liehr RM, et al. Endosonography of neuroendocrine tumors of the stomach, duodenum, and pancreas. Ann N Y Acad Sci. 1994;733: 425-36.
 14. Regge D, Lo Bello G, Martincich L, et al. A case of bleeding gastric lipoma: US, CT and MR findings. European Journal of Radiology. 1999;9:256-8.
 15. Heye T, Kuntz C, Dux M, et al. CT and endoscopic ultrasound in comparison to endoluminal MRI: Preliminary results in staging gastric carcinoma. European Journal of Radiology. 2009;70:336-41.
 16. Matsushiata M, Oi H, Murakami T, et al. Extraserosal invasion in advanced gastric cancer: Evaluation with MR imaging. Radiology. 1994;192:87-91.
 17. Greene FL, Page DL, Fleming ID et al. AJCC manual of staging of cancer. Springer-Verlag, New York, 6th edn; 2002.
 18. Xianying H, Kuangsheng Y, Yuexia S, et al. Clinical value of magnetic resonance imaging in preoperative T staging of gastric cancer and postoperative pathological diagnosis. Oncology Letters. 2014;8:275-280.
 19. Sohn KM, Lee JM, Lee SY, et al. Comparing MR imaging and CT in the staging of gastric carcinoma. AJR Am J Roentgenol. 2000;174:1551-1557.
 20. Goldberg HI, Thoeni RF. MRI of the gastrointestinal tract. Radiol Clin North Am. 1989;27:805-812.
 21. Halvorsen RA Jr, Thompson WM. Primary neoplasms of the hollow organs of the gastrointestinal tract. Staging and follow-up. Cancer. 1991;67:1181-1188.
 22. Campeau NG, Johnson CD, Felmler JP, et al. MR imaging of the abdomen with a phased-array multicoil: Prospective clinical evaluation. Radiology. 1995;195:769-778.
 23. Palmowski M, Grenacher L, Kuntz C, et al. Magnetic resonance imaging for local staging of gastric carcinoma: Results of an *in vitro* study. J Comput Assist Tomogr. 2006;30:896-902.

© 2020 Ahmad et al.; This is an Open Access article distributed under the terms of the Creative Commons Attribution License (<http://creativecommons.org/licenses/by/4.0>), which permits unrestricted use, distribution, and reproduction in any medium, provided the original work is properly cited.

Peer-review history:
The peer review history for this paper can be accessed here:
<http://www.sdiarticle4.com/review-history/58432>