

Cervical Myelopathy: Diagnostic Aspects, Surgical Treatment and Evolution of Patients Operated upon in Yaounde

Bello Figuim^{1*}, Djoubairou Ben Ousmanou², Oumarou Haman Nassourou¹,
Ndome Toto Orlande³, Amadou Tidjani⁴, Djientcheu Vincent de Paul¹

¹Yaounde Central Hospital, Faculty of Medicine and Biomedical Sciences of the University of Yaounde 1, Yaounde, Cameroon

²Yaounde Military Hospital, Faculty of Medicine and Pharmaceutical Sciences of the University of Douala, Douala, Cameroon

³Douala General Hospital, Faculty of Medicine and Pharmaceutical Sciences of the University of Douala, Douala, Cameroon

⁴Higher Institute of Health Sciences, Université des Montagnes, Bangangté, Cameroon

Email: *bellofiguim@gmail.com

How to cite this paper: Figuim, B., Ben Ousmanou, D., Nassourou, O.H., Orlande, N.T., Tidjani, A. and de Paul, D.V. (2024) Cervical Myelopathy: Diagnostic Aspects, Surgical Treatment and Evolution of Patients Operated upon in Yaounde. *Open Journal of Modern Neurosurgery*, **14**, 72-82.

<https://doi.org/10.4236/ojmn.2024.141008>

Received: October 10, 2023

Accepted: January 13, 2024

Published: January 16, 2024

Copyright © 2024 by author(s) and Scientific Research Publishing Inc.

This work is licensed under the Creative Commons Attribution International License (CC BY 4.0).

<http://creativecommons.org/licenses/by/4.0/>



Open Access

Abstract

Introduction: Although cervical myelopathy is the most common degenerative cervical spine pathology in adults, the indications and approaches of surgical treatment have not yet been clearly defined in the literature. Very few studies exist regarding these aspects in our setting, and they are mostly outdated. This study aimed to describe the diagnostic aspects, current surgical treatment with technical improvements, and progression in patients. **Patients and Methods:** We conducted a multicentre retrospective descriptive study over a 10-year period between January 2011 and January 2020 in three referral centres in Yaoundé. All patients who underwent surgery for cervical myelopathy were included. **Results:** Fifty-two patients were recruited. The rate of operated cervical myelopathies among all degenerative spinal pathologies was 14.05%. The M/F sex ratio was 3/1, and the average age was 52 ± 10 years. All included patients had gait problems, 90.38% demonstrated motor deficiency, and 67.30% experienced at least three levels of compression. Surgery was decided based on the Nurick grade; a posterior approach was applied to 86.54% of patients. Postoperative progression showed a neurological improvement of 82% with an average follow-up of 4 years. **Conclusion:** In this study, the patients who underwent surgery were relatively young, their clinical presentations were mostly advanced, and surgical management showed good results in well-selected cases.

Keywords

Cervical Myelopathy, Diagnosis, Treatment, Evolution, Cameroon

1. Introduction

Cervical myelopathy is a spinal cord disorder resulting from a reduction of the cervical diameter of the spinal canal due to degenerative phenomena [1]. It accounts for 55% of myelopathies in adults over the age of 50 years [2] [3] and is caused by static and dynamic factors [4] [5]. The clinical presentations include the ataxospasmodic form, where gait and balance disorders predominate; amyotrophic form, in which the upper limbs are predominantly affected; spastic paraparesis form; Brown Sequard syndrome form; and the forms evolving with progression [6]. The common combination of clinical presentation is clumsiness of the hands, gait problems, and progressive cervicobrachial neuralgia [7]. Magnetic resonance imaging (MRI) is the preferred diagnostic examination, supplemented by computed tomography (CT) and standard radiography [8]. The value of dynamic cervical MRI in surgical planning has also been demonstrated in the literature [5] [9]. The goal of surgical treatment is to prevent neurological worsening [10] by decompressing the spinal cord and roots and restoring adequate spinal statics. The surgical decision in the case of cervical myelopathy is based on radiological criteria (compression of the spinal cord with absence of cerebrospinal fluid [CSF] around the cord, the presence of spinal hypersignal in a T2-weighted sequence) and clinical criteria (progression of neurological symptoms and deficits with significant and recent functional effects). The surgical approach can be anterior, posterior, or combined. Surgery can be indicated by the Nurick grade and the modified Japanese Orthopaedic Association (mJOA) score. However, in our context, the few available studies that have described the clinical and surgical aspects of the treatment in patients were published two decades ago. With the technical improvements, in particular, the availability of MRI devices and the creation of new neurosurgery centres, the recommendations proposed in the literature have been increasingly incorporated in patient management. Thus, it is important to determine the Nurick grade at which surgery leads to good functional outcomes and the arguments in the context of our research that led to choosing the anterior or posterior approach. Therefore, this study aimed to describe the clinical presentation, current surgical treatment, and progression of cervical myelopathy.

2. Materials and Methods

2.1. Type of Study and Location

This was a 10-year retrospective and descriptive cross-sectional study conducted between January 2011 and January 2020 in the neurosurgery departments of the Central Hospital, the Military Hospital, and the General Hospital of Yaoundé. These neurosurgery centres are the only ones in Yaoundé and they supervise the university neurosurgery training programme in Cameroon.

2.2. Study Population and Inclusion Criteria

All complete medical files of patients who underwent surgery for cervical mye-

lopathy during the study period were consecutively included. The diagnosis of cervical myelopathy was made using spinal MRI; additionally, in some cases a CT scan of the cervical spine was used in cases where MRI was unavailable. Standard radiography was systematic. Severity of myelopathy was assessed using the Nurick grade.

2.3. Study Variables

The variables of the study were obtained from medical files: age; sex; circumstances of discovery; clinical presentation; imaging data of radiography, CT, and MRI (static disorder, area of compression, level of compression, and signs of spinal cord injury); surgical treatment (indications and approaches); and the progression of patients who underwent surgery. Patients were followed up in an outpatient setting at 3 months, 6 months, 1 year, and on demand depending on their progress. Patients living far away from neurosurgery centres were contacted by telephone for follow-up after 1 year. The postoperative evaluation was clinical using the Nurick grade (Nurick classification system) at six months and one year, and we asked X ray for patients who had undergone stabilisation to assess the correct placement of the implant and to evaluate sagittal balance.

Grade	Nurick classification system
0	No root or cord symptom
1	Roots signs or symptoms. No evidence of cord involvement
2	Signs and cord involvement. Normal gait
3	Gait abnormality. Able to be employed
4	Gait abnormality prevents employment. Able to ambulate only with assistance
5	Chair bound or bedridden

2.4. Statistical Analysis

The data were analysed using the Epi info software 7.2.2.6 and Excel 2013.

2.5. Ethical Consideration

The protocol of our study was submitted to the University and we have obtained ethical clearance of this study. We have also obtained administrative authorizations from Central Hospital, Military Hospital and General Hospital of Yaounde.

3. Results

Overall, 61 patients were operated on for cervical myelopathy during the study period out of 434 patients who underwent surgery for degenerative pathologies of the spine, *i.e.*, a rate of 14.05%. We retained 52 patients: 26 patients from Central Hospital, 14 patients from Military Hospital and 12 patients from General Hospital as showed in **Diagram 1**.

3.1. Demographic, Clinical, and Radiological Characteristics

The average age was 52 ± 10 years with extremes between 40 and 82 years. The predominant age group was between 50 and 65 years (Figure 1). The M/F sex ratio was 3/1. The onset of symptoms was progressive in 86.54% and post-traumatic in 13.46% of the patients. The main clinical presentation was gait problems (100%) associated with cervicobrachial neuralgia (59.62%); motor deficiency was noted in 47 patients (90.38%), sphincter disorders in 8 patients (11.38%), and sexual problems in 3 patients (5.77%) (Table 1). The diagnosis was made with MRI in 76.92% and CT in 23.07%. All patients underwent standard radiography. Most patients (67.30%) had three or four levels of compression, and spinal hypersignals were present in 9 patients (22.50%) (Table 2). The Nurick classification was grade 0 and 1 (0%), grade 2 (17.31%), grade 3 (38.46%), grade 4 (32.69%), and grade 5 (11.54%).

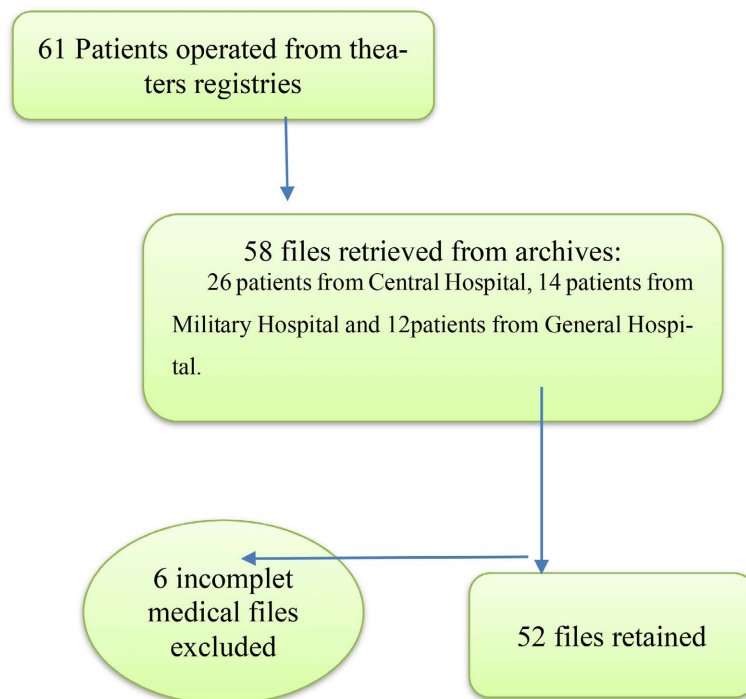


Diagram 1. Flow diagram.

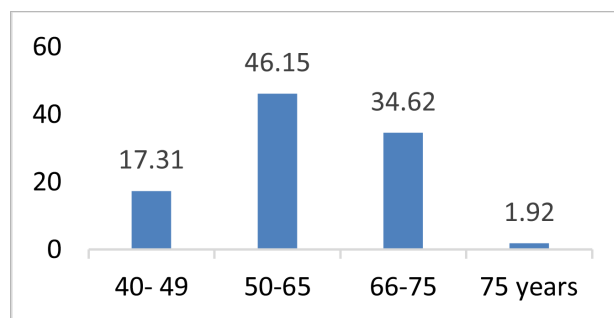


Figure 1. Patient age range distribution

Table 1. Clinical presentation.

Variables	Number (N = 52)	Percentage (%)
Cervicalgia	22	42.31
Radicular pain	31	59.62
Motor deficit	47	90.38
Sphinters disorders		
Dysuria	04	7.69
Bladder incontinence	04	7.69
Sexual weakness	03	5.77

Table 2. Radiological presentation.

Variables	Number (N = 52)	Percentage (%)
Radiological assessment		
MRI	40	76.92
CT scan	12	23.07
Cervical X ray	52	100
Radiological lesion		
Number of level		
2 levels	17	32.69
3 level	21	40.38
≥4 levels	14	26.92
Sign of myelopathy		
No T2-weighted hypersignal	31	77.50
T2-weighted hypersignal	09	22.50

3.2. Surgical Treatment and Evolution

The surgical indication was decided based on the Nurick grade. Grades 3 (38.46%) and 4 (32.69%) represented the majority of indications (**Figure 2**). The surgical approach was posterior in 86.54%. Decompressive laminectomy was used in all cases with stabilisation in 8% of cases. The anterior approach was performed in 13.46% of cases. It involved a discectomy with the placement of a graft and a screwed plate. The anterior approach was essentially used in patients with one or two levels of compression. The postoperative progression at one year using the Nurick grade showed an improvement in 82%, no progression in 8%, and a worsening in 6% of patients (**Figure 3** and **Figure 4**). Notably, 21% of the patients had a follow-up at 2 years, and the average follow-up of patients was 4 years with a range of 1 - 10 years.

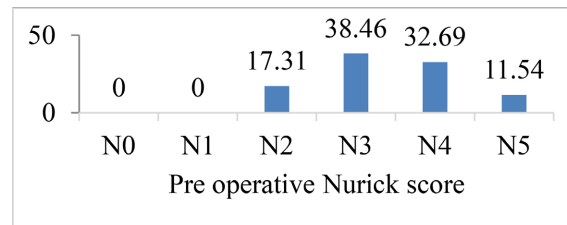


Figure 2. Pre-operative Nurick score.

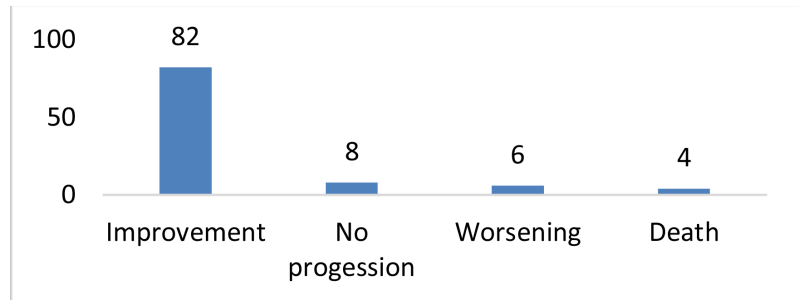


Figure 3. One-year post-operative evolution.

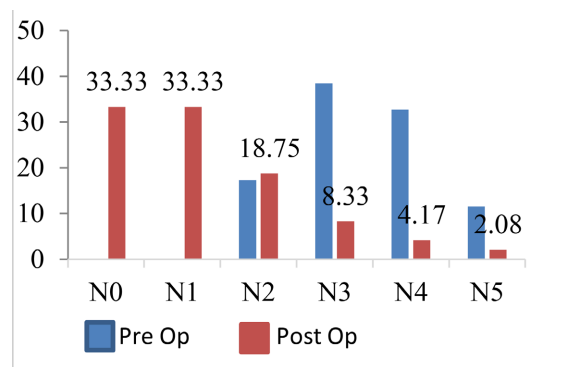


Figure 4. Pre and post-operative Nurick score evolution at one year.

4. Discussion

The patients who underwent surgery during the study period were relatively young and predominantly male. The clinical presentations were mostly advanced. In addition to MRI, we used radiography to evaluate the spinal statics. Three quarters of the patients had three or four levels of compression. The surgical indication was based on the Nurick grade: the majority of patients had grades 3 and 4. The surgical approach was anterior in the case of one or two levels and posterior in the case of 3 levels or more. The progression after surgery was characterised by an improvement in the neurological condition in the majority of cases.

4.1. Demographic Characteristics

Cervical myelopathy is a relatively common pathology in our environment. It represents 14% of surgical indications among degenerative spinal pathologies. The most represented age group was between 50 and 65 years; the average age of

the patients was 52 ± 10 years. In Morocco, Djoubairou *et al.* [11] also found in 2014 that the average age of patients was 52 years. This relatively young age was also predominant in other African studies [12]-[17] compared to Western studies, where the average age was higher [1] [5] [9].

4.2. Clinical Characteristics

The onset of symptoms is usually progressive for the given clinical form. Cervical myelopathy can appear following trauma. In our series, 13.46% of patients presented with decompensated myelopathy due to cervical spine trauma. Previous studies have reported that 15% to 20% of patients are admitted after decompensation following cervical spine trauma [12] [13]. The clinical presentation consists predominantly of gait problems (100%), followed by cervicobrachial neuralgia (59.62%) and neck pain (42.31%). In particular, this is the usual clinical presentation of cervical myelopathy. The radicular or medullary signs depend on the level of compression. Gait problems can be of the cord type in the case of posterior compression and spastic in the case of anterior compression. Neck pain is generally found in a static disorder. Almost all patients had a sublesional motor deficit (90.38%). Nurick grades 4 and 5 were found in one-third and 11% of patients, respectively, indicating late arrival of patients for a neurosurgery consultation, which poses a problem in diagnosing of cervical myelopathy. Notably, Nyada *et al.* [14] in Cameroon, Hima Maiga *et al.* [12] in Niger, and Loembe [15] in Gabon also found similar results.

4.3. Radiological Characteristics

MRI is the preferred examination method to assess the elements of anterior (herniated disc, ossification of the posterior common vertebral ligament) and posterior (hypertrophy of the yellow ligament) compressions. It is also used to detect the presence of a medullary hypersignal in a T2-weighted sequence or a spinal hypsignal in a T1-weighted sequence, which is a factor of poor prognosis [16]. CT is performed for bone assessment, and dynamic radiography for the analysis of spinal statics. Dynamic cervical MRI has reportedly been valuable in surgical planning [9]. MRI was performed in 76.92% and CT in 23.07%. MRI has been the systematic examination for almost 6 years, but patients who underwent surgery and were examined with CT were older. The medullary hypersignal was found only in 22% of the patients and the majority of the patients had at least three levels of compression.

4.4. Surgical Treatment and Evolution

The goal of the treatment is to prevent a deterioration in the neurological status of the patients. The surgical decision in the case of cervical myelopathy is based on radiological criteria (compression of the spinal cord with absence of CSF around the cord, the presence of spinal hypersignal in a T2-weighted sequence), and clinical criteria (progression of neurological symptoms and deficit with sig-

nificant and recent functional effects). In this study, surgery was indicated for a Nurick grade ≥ 2 . All patients who underwent surgery with a Nurick grade of 5 (11%) had experienced cervical spine trauma leading to decompensation of the pre-existing myelopathy. Of them, 86.54% underwent the posterior approach, which was similar to the results of Hima Maiga *et al.* [12] whose approach was exclusively posterior. This result was unlike those of Ahanogbe *et al.* [17] with a series of 12 cases in Togo and Loembe *et al.* in Gabon [15] where the approach was anterior in 83.33% and 100% of patients, respectively. In this study, an anterior approach was applied in a patient with one or two levels of compression (**Image 1**), in which discectomy with iliac graft or cage and a screwed plate was performed (**Image 2**). The posterior approach was indicated in patients with three or more levels of compression (**Image 1**), in which laminectomy was performed. Posterior stabilisation (**Image 3**) was indicated in patients with kyphosis or mobile listhesis shown on dynamic radiography. The progression at 1 year after surgery measured by the Nurick grade showed an improvement in the neurological status in 82%. Prognostic factors include age, duration of symptoms, preoperative neurological status [18], and the presence of a hyposignal in a

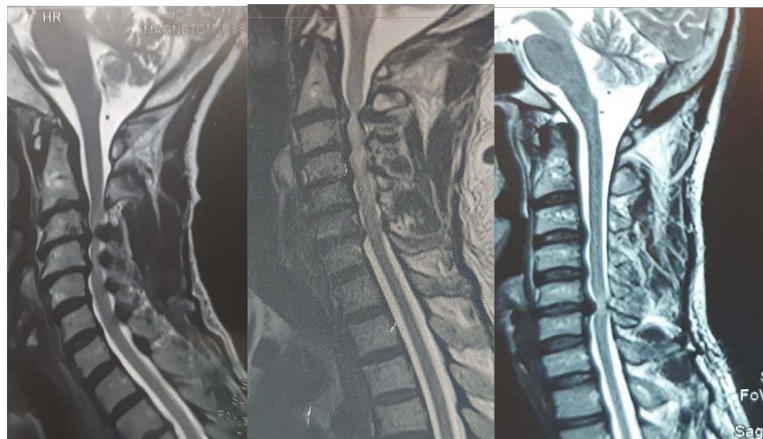


Image 1. Left: MRI: C3-C6 cervical myelopathy: hypertrophy of the yellow ligaments; Middle: MRI: C2-C7 cervical myelopathy: T2-weighted hypersignal; Right: MRI: C5C6 cervical myelopathy by disc herniation with hypersignal.

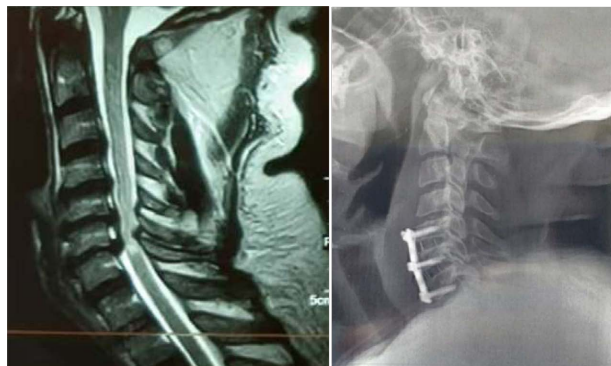


Image 2. Left: cervical spine MRI, sagittal view: C5-C6-C7 cervical myelopathy. Right: control x ray anterior approach C5-C6, C6-C7, discectomy, cage and plate.

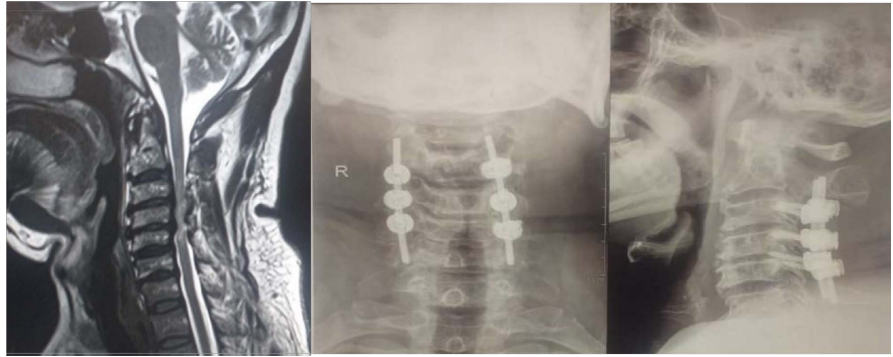

Image 3. Left: cervical spine MRI, sagittal view: C3-C4-C5 cervical myelopathy with a mild kyphosis. Right: control x ray, posterior approach C3-C4-C5, laminectomy and stabilization.

T1-weighted sequence [16]. In our study, clinically speaking, 63.46% of patients were under 65 years of age and 71.15% were classified as Nurick grades 3 and 4. On the radiological level, there was a spinal cord hypersignal in the T2 sequence in 22.5%, and no patient had a spinal cord hyposignal in the T1 sequence. The study involved relatively young patients, most of whom did not show severe signs of myelopathy on MRI. Bedridden patients were those who had experienced cervical spine trauma. In Hima Maiga *et al.*'s study [12], half of the patients who underwent surgery and were considered to have Nurick grade 5 remained in the same condition and the condition worsened in 20%.

4.5. Study Limitations

This was a retrospective study and the data obtained by telephone during the postoperative evaluation at one year constituted the limit in terms of their reliability.

5. Conclusion

Cervical myelopathy is a relatively common pathology in our environment. In our study, the patients who underwent surgery were relatively young, the clinical presentations were mostly advanced, and most of the patients arrived late for their neurosurgery consultation. In addition to MRI, we used radiography to evaluate the spinal statics. The surgical indication was based on the Nurick grade and the surgical approach depended on the number of compression levels. The progression after surgery was characterised by an improvement in the neurological condition in the majority of cases.

Conflicts of Interest

The authors declare no conflicts of interest regarding the publication of this paper.

References

- [1] McCormick, J.R., Sama, A.J., Schiller, N.C., Butler, A.J. and Donnally, C.J. (2020) Cervical Spondylotic Myelopathy: A Guide to Diagnosis and Management. *Journal*

- of the American Board of Family Medicine, **33**, 303-313. <https://doi.org/10.3122/jabfm.2020.02.190195>
- [2] Toledano, M. and Bartleson, J.D. (2013) Cervical Spondylotic Myelopathy. *Neurologic Clinics*, **31**, 287-305. <https://doi.org/10.1016/j.ncl.2012.09.003>
- [3] Boudissa, M., Lebecque, J., Boissière, L., Gille, O., Pointillart, V., Obeid, I. and Vital, J.M. (2016) Earlier Reoperation after Cervical Spine Surgery by Anterior Approach: Épidémiology and Risk Factors. Case Control Study. *Revue de Chirurgie Orthopédique et Traumatologique*, **102**, 349-352. <https://doi.org/10.1016/j.otsr.2016.02.003>
- [4] Oliveira, C., Orsini, M., Leite, M.A., de Freitas, M.R., Davidovich, E., Fiorelli, R., et al. (2016) Cervical Spondylotic Myelopathy: What the Neurologist Should Know. *Neurology International*, **8**, 69-73. <https://doi.org/10.4081/ni.2016.6330>
- [5] Lee, J.B., Kim, I.S., Kwon, J.Y., Lee, J.J., Park, J.H., Cho, C.B., et al. (2019) Difference of Dynamic Morphometric Changes between in Patients with Ossification of Posterior Longitudinal Ligament and Patients with Cervical Spondylosis: Assessment by Cervical Dynamic Magnetic Resonance Imaging. *World Neurosurgery*, **125**, 566-573. <https://doi.org/10.1016/j.wneu.2018.11.213>
- [6] Brunon, J., Nuti, C., Duthel, R., Fotso, M. and Dumas, B. (2005) Cervical Mtelopathy. *Ency Méd Chir, Neurologie*, **660**, 14-17.
- [7] Mourad, B. (2007) Clinical Evaluation of Cervical Myelopathy Surgery. About 82 Cases. *JDN*, **3**, 1-10.
- [8] Aljuboori, Z. and Boakye, M. (2019) The Natural History of Cervical Spondylotic Myelopathy and Ossification of the Posterior Longitudinal Ligament: A Review Article. *Cureus*, **11**, e 5074. <https://doi.org/10.7759/cureus.5074>
- [9] Solène, P., Kaissar, F., Aurélie, T., Nacer, M., Benjamin, B. and Stéphane, F. (2023) Contribution of Cervical Dynamic MRI for Surgical Planification of Cervical Myelopathy: Five Years Outcome. *Revue de Chirurgie Orthopédique et Traumatologique*, **109**, 184-191.
- [10] Jamie, R.F.W., Jetan, H.B., Ali, M., Allan, R.M. and Michael, G.F. (2019) Degenerative Cervical Myelopathy; a Review of the Latest Advances and Future Directions in Management. *Neurospine*, **16**, 494-505. <https://doi.org/10.14245/ns.1938314.157>
- [11] Djoubairou, B.O., Nabil, M., Karekezi, C., Diawara, S., El Fatemi, N., Gana, R., et al. (2014) Cervical Myelopathy: Clinical and Radiological Results of 135 Operated Patients at the Neurosurgical Unit of CHU Avicenne. *Pan African Medical Journal*, **29**, 1-7. <https://doi.org/10.11604/pamj.2014.19.29.4481>
- [12] Hima Maiga, A., Kpelao, E., Kelani, A.B., Abdoulwahab, I., Gaye, M., Avop, A., et al. (2020) Cervical Myelopathy at the Era of CT Scan and MRI in Niger. *Médecine d'Afrique Noire*, **67**, 457-470.
- [13] Samia, E. (2020) Cervical Myelopathy. University of Sidi Mohamed ben Abdallah, Marrakech, 151 p.
- [14] Nyada, S.R., Mveng, F., Zogo, P.O., Eyenga, V.C. and Ngah, J.E. (2020) Myelopathy Due to Cervical Spondylosis in Yaoundé: Clinical Features and Treatment. *International Journal of Innovative Studies in Medical Sciences*, **4**, 4-7.
- [15] Loembe, P.M., Kouona, N.P., Mwanyombet, O.L., Assengone, Z.Y., Odimba, R.U. and Koumba, J. (2004) Cervical Myelopathy. Long Term Results of 18 Operated Patients by Anterior Approach in Gabon. *African Journal of Neurological Sciences*, **23**, 1-5. <https://doi.org/10.4314/ajns.v23i1.7549>
- [16] Avadhani, A., Rajasekaran, S. and Shetty, A.P. (2010) Comparison Value of Different MRI Classifications of Signal Intensity Change in Cervical Spondylotic Myelopathy. *The Spine Journal*, **10**, 475-485. <https://doi.org/10.1016/j.spinee.2010.03.024>

- [17] Ahanogbe, K.M.H., Beketi, K.A., Kpelao, E., Moumouni, A., Doleagbnou, K. and Egbohoun, P. (2018) Cervical Myelopathy of Operated Patients in Togo by Anterior Approach: Yes but Not Always. *Neurochirurgie*, **64**, 238-239.
<https://doi.org/10.1016/j.neuchi.2018.05.057>
- [18] Langston, T.H., Paul, G.M., Paul, A.A., Michael, W.G., Robert, F.H., Michael, G.K., *et al.* (2009) Clinical Prognostic Indicators of Surgical Outcome in Cervical Spondylotic Myelopathy. *Journal of Neurosurgery: Spine*, **11**, 112-118.
<https://doi.org/10.3171/2009.1.SPINE08718>