



Vanek's Tumour Unveiled: Decoding Enigmatic Intricacies at the Ileocecal Junction

**M. Anajjar ^{a,b*}, A. Fadili ^a, P. Nsengiyumva ^a, A. Akhdamch ^a,
W. Atmani ^b, A. Rehali ^a, Y. Elbrahmi ^a, N. Njoumi ^a,
M. Yakka ^a, M. Elfahssi ^a, A. Elhajjouji ^a and A. Aitali ^{a,b}**

^a *Department of Visceral Surgery II, Mohammed V Military Teaching Hospital, Mohammed V University, Rabat, Morocco.*

^b *Faculty of Medicine and Pharmacy, Mohammed V University, Rabat, Morocco.*

Authors' contributions

This work was carried out in collaboration among all authors. All authors read and approved the final manuscript.

Article Information

Open Peer Review History:

This journal follows the Advanced Open Peer Review policy. Identity of the Reviewers, Editor(s) and additional Reviewers, peer review comments, different versions of the manuscript, comments of the editors, etc are available here: <https://www.sdiarticle5.com/review-history/109592>

Case Study

Received: 18/09/2023

Accepted: 25/11/2023

Published: 29/11/2023

ABSTRACT

Aims: Inflammatory Fibroid Polyps (IFPs) present a diagnostic enigma in gastrointestinal pathology, with their rarity and elusive clinical nature. This article details the case of a 65-year-old patient experiencing chronic abdominal pain and sub-occlusion symptoms, exemplifying the diagnostic complexities associated with IFPs.

Presentation of Case: A 65-year male patient, with no prior medical history, underwent extensive clinical evaluation, including a colonoscopy and abdominal CT scan, which failed to identify the underlying cause for his chronic pain. Exploratory laparoscopy revealed a 2.5 cm mass in the terminal ileum, leading to necessary ileocecal resection. Postoperative recovery was uneventful, with resolved anemia and a two-year follow-up showing no recurrence.

*Corresponding author: E-mail: Mohamed.anajjar@um5s.net.ma;

Discussion: Vanek's 1949 introduction of the term "IFP" described them as "gastric submucosal granulomas with eosinophilic infiltration." Over a thousand cases have been reported, with 23% originating in the small intestine, particularly the ileum. Despite their often-inflammatory nature, no specific causal factor has been pinpointed. IFPs are usually asymptomatic but may present with dyspepsia, bleeding, or discomfort. Differential diagnosis includes spindle cell lesions and gastrointestinal stromal tumors.

Conclusion: Treatment options depend on the size and location of the polyp. Surgical resection or endoscopic excision is preferred for symptomatic cases. This article emphasizes the diagnostic challenges posed by IFPs, urging heightened awareness among healthcare professionals. IFPs demand inclusion in the differential diagnosis of gastrointestinal pathologies to ensure timely and appropriate management.

Keywords: Inflammatory fibroid polyps; gastrointestinal pathology; ileocecal junction diagnostic challenges; surgical resection; Vanek's tumour.

1. INTRODUCTION

Inflammatory Fibroid Polyps (IFPs) are a rare and enigmatic entity within the realm of gastrointestinal pathology, known for their diagnostic elusiveness [1]. These lesions, first described by Vanek in 1949 [2], continue to present clinicians with formidable challenges, particularly when situated in the junction of the ileocecal region. This diagnostic complexity is exemplified through a case report of a 65-year-old patient we encountered in our clinical practice.

The rarity of IFPs, combined with their often-elusive clinical presentation, adds an additional layer of complexity to the diagnostic process. Our patient's unique case, which we present in this

article, offers a compelling illustration of the diagnostic intricacies commonly associated with this pathology.

2. PRESENTATION OF CASE

A 65-year-old patient, with no prior medical history, was referred for evaluation due to persistent chronic abdominal pain and recurring sub-occlusion symptoms over the past two years. The initial clinical examination revealed a patient in excellent general condition, with a soft abdomen and no palpable masses. The rectal examination was normal and did not reveal any melena.

The preoperative assessment showed a low ferritin level and a hemoglobin of 10 g/dL. Tumor markers were within normal limits.

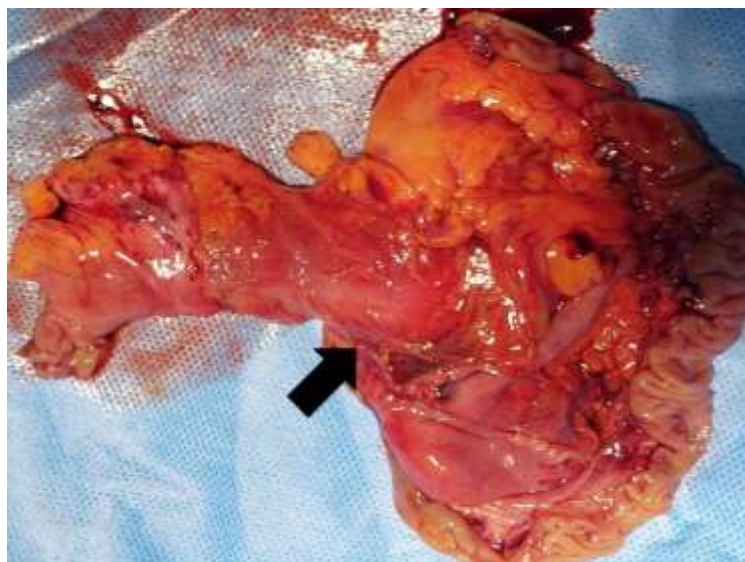


Fig. 1. External aspect of the ileocecal resection, the black arrow shows the bulge of the polyp in the last loop of the ileum

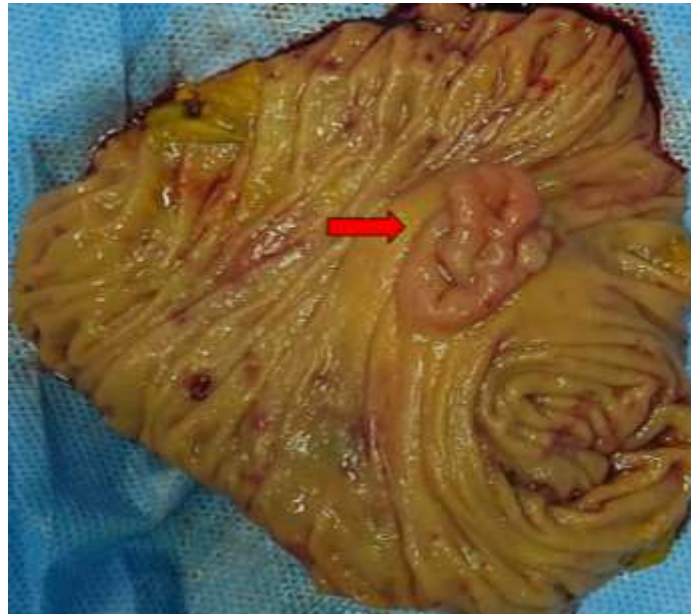

Fig. 2. Endoluminal aspect after eversion of the polyp shown by the red arrow

A complete colonoscopy did not identify any abnormalities in the colon, and neither did an abdominal CT scan. Consequently, an exploratory laparoscopy was conducted to investigate the possible presence of a small tumor that might have been missed by the CT scan. During the laparoscopy, the liver and stomach appeared healthy. A thorough examination of the small intestine was performed, involving gentle unrolling and palpation using an atraumatic fenestrated clamp. It was in the terminal portion of the last ileal loop that a firm, fixed 2.5 cm mass was discovered. As a result, an ileocecal resection was deemed necessary.

Mobilization of the right colon and the last ileal loop occurred under laparoscopy before converting to a median laparotomy through a mini-incision to complete the ileocolic lateral-to-lateral anastomosis using a 75 mm linear clamp. Postoperative recovery was uneventful, with the resumption of a liquid diet on the first day and discharge from the hospital on the fourth day.

In the postoperative period, the anemia resolved, and the ferritin level returned to 150 ng/mL. The patient was followed up in outpatient care for two years without any signs of recurrence or specific complaints.

3. DISCUSSION

- In 1949, Vanek used for the first time the term "IFP" to refer to a "gastric submucosal

granuloma with eosinophilic infiltration." [2] At least 1000 IFP have been reported so far in the literature, with 23% of them originating in the small intestine (mostly the ileum) [3]

- IFPs are often referred to as reactive or inflammatory lesions. However, no particular stimulus or causal factor has been found. Due to the presence of eosinophils, Vanek proposed that an allergy aetiology may be present. However, looked implausible given the absence of peripheral eosinophilia and the fact that eosinophils are not present in all IFPs [4].

Diagnostic

- IFPs are asymptomatic, typically incidentally diagnosed via an endoscopy or laparotomy [2]. When they exhibit symptoms such as dyspepsia, bleeding, stomach discomfort, and weight loss. Both the size and the location of the lesion affect the clinical appearance. Small intestine IFPs frequently appear with intussusception [4].
- Inflammatory lesions of the GI tract and other benign and malignant proliferative spindle cell lesions are included in the differential diagnosis of IFP. IFPs must be distinguished from GISTs since they do not recur or spread like GISTs do. [4].

Treatment

- According to the size of the polyp, surgical resection or endoscopic excision are the preferred treatments in symptomatic situations. [4].
- Surgical resection is the optimal treatment method for Inflammatory Fibroid Polyps (IFPs) accompanied by intussusception [5] However, for IFPs less than 2 cm in size and within 10 cm of the ileocecal valve, removal by colonoscopy has been proven to be less invasive, safe, and effective [6]. IFPs in the terminal ileum have corresponding colonoscopic and endoscopic ultrasonographic features [7]. Colonoscopic minimally invasive dissection and resection have been successfully performed for IFPs in the terminal ileum, with no postoperative complications or recurrence during follow-up [8]. Surgical resection is generally accepted as the treatment modality for IFPs due to their relatively large size and difficulty in endoscopic resection using standard techniques [9]. However, there have been reports of successful endoscopic resection of colonic IFPs using novel techniques such as trapping the stalk with an endoloop and dissecting it with a needle knife.
- Colorectal and duodenal polyps may apparently be removed safely and effectively using underwater endoscopic mucosal resection (UEMR) [10], and may be of interest for IFP resection.
- in our patient due to a lack of catheterisation of the last loop of the ileum, which did not allow a preoperative diagnosis, and for this reason we were unable to offer him endoscopic treatment, despite the high probability of failure given the large size, and we will end up operating on him.

4. CONCLUSION

Inflammatory Fibroid Polyps (IFPs) remain a mystery in the field of gastrointestinal pathology, primarily due to their rarity and polymorphic clinical presentation. Our experience with this case, located at the ileocecal junction, perfectly illustrates the diagnostic challenges posed by IFPs.

The rarity of IFPs and the variability of their clinical manifestations emphasize the importance

of heightened vigilance among healthcare professionals. It is crucial to emphasize the inclusion of IFPs in the differential diagnosis of gastrointestinal pathologies. Physicians must keep these enigmatic lesions in mind to ensure proper and early management.

ETHICAL APPROVAL

As per international standard or university standards written ethical approval has been collected and preserved by the author(s).

CONSENT

As per international standards or university standards, patient(s) written consent has been collected and preserved by the author(s).

COMPETING INTERESTS

Authors have declared that no competing interests exist.

REFERENCES

1. Souiki T, Mazaz K. Inflammatory fibroid polyp causing ileo-ileal intussusception. Pan Afr Med J [Internet]. [cited 2023 Jul 17] May 16 2022;42(36). Available: <https://www.panafrican-med-journal.com/content/article/42/36/full>
2. Toydemir T. Inflammatory fibroid polyp of the ileum presenting with small bowel obstruction in an adult patient: a case report. J Med Case Reports. 2010 Aug 30;4:291.
3. Rabbani K, Narjis Y, Jgounni R, Semlani Z, Difaa A, Benelkhaiat R, et al. Adult intussusception caused by an inflammatory fibroid ileal polyp. Acta Chir Belg. 2012; 112(2):157–9.
4. Smith-Chakmakova F, Liu YJ, Karamchandani DM. Inflammatory Fibroid Polyp of the Ileocecal Valve: Case Report, Review, and Recent Advances. Ann Clin Lab Sci. 2015;45(4): 441–5.
5. Tang YS, Liu L, Gao Y, He QC, Guo HM, Zhao ZF. Minimally invasive colonoscopy treatment of inflammatory fibroid polyps in the terminal ileum. Sci Rep. 2023 Mar 26;13:4929.
6. Ivaniš N, Tomas V, Vranić L, Lovasić F, Ivaniš V, Žulj M, et al. Inflammatory Fibroid

- Polyp of the Small Intestine: A Case Report and Systematic Literature Review. J Gastrointest Liver Dis JGLD. 2020 Sep 9;29(3):455–60.
7. Park KB, Jee YS, Kim DW. Laparoscopic resection of two inflammatory fibroid polyps: An unusual cause of jejunojejunal intussusception. Int J Surg Case Rep. 2020;69:20–3.
 8. Loop observe and snare technique for endoscopic resection of a gastric inflammatory fibroid polyp. Endoscopy [Internet]. Mar 6 2012;44. [cited 2023 Nov 10]
 9. Available: <https://typeset.io/papers/loop-observe-and-snare-technique-for-endoscopic-resection-of-449xsz50w>
 9. Kim Byeong-Chang, Sang-Gil Lee, Tae-Il Kim, Ho-Geun Kim, Won-Ho Kim, Cheon Jae-Hee. Needle Knife-assisted Endoscopic Polypectomy for a Large Inflammatory Fibroid Colon Polyp by Making Its Stalk into an Omega Shape Using an Endoloop. Yonsei Med J. 2008 Jan;49(4):680–6.
 10. Sakurai H, Takeuchi Y, Shichijo S. Underwater endoscopic mucosal resection for a large polyp in the terminal ileum. Dig Endosc Off J Jpn Gastroenterol Endosc Soc. 2021 Sep;33(6):e140–1.

© 2023 Anajjar et al.; This is an Open Access article distributed under the terms of the Creative Commons Attribution License (<http://creativecommons.org/licenses/by/4.0>), which permits unrestricted use, distribution, and reproduction in any medium, provided the original work is properly cited.

Peer-review history:
The peer review history for this paper can be accessed here:
<https://www.sdiarticle5.com/review-history/109592>