



An Uncommon Presentation of Axial Torsion with Ischemic Perforation of Meckel's Diverticulum

Hian Ee Heng ^{a,b*}, Wong Jo-Lin ^{a,b} and Teh Mei Sze ^{a,b}

^a Department of Surgery, University Malaya Medical Centre, Kuala Lumpur, Malaysia.

^b Faculty of Medicine, University Malaya, Kuala Lumpur, Malaysia.

Authors' contributions

This work was carried out in collaboration among all authors. All authors read and approved the final manuscript.

Article Information

Open Peer Review History:

This journal follows the Advanced Open Peer Review policy. Identity of the Reviewers, Editor(s) and additional Reviewers, peer review comments, different versions of the manuscript, comments of the editors, etc are available here: <https://www.sdiarticle5.com/review-history/104137>

Case Report

Received: 07/06/2023

Accepted: 10/08/2023

Published: 18/08/2023

ABSTRACT

Introduction: Meckel's diverticulum (MD) is the commonest congenital anomaly of the gastrointestinal tract due to incomplete obliteration of the vitellointestinal duct. Most of the patients were asymptomatic with only 4% of them presented with complications. Axial torsion leading to ischemic perforation of MD is a rare presentation with only few cases reported in the literature.

Case Summary: A 25 year old man presented with two days acute severe abdominal pain with evidence of peritonism over the lower abdomen. He was posted for an urgent laparotomy with a preoperative diagnosis of perforated appendicitis. An emergency laparotomy was performed and the intraoperative diagnosis was axial torsion of the MD with purulent peritonitis. The MD had a narrow base with a length of 6cm and was attached anteriorly via a mesodiverticular band. A wedge resection with primary repair was performed with peritoneal lavage. Patient recovered well and was discharged home seven days after the surgery. The histopathological report of the specimen was consistent with ischemic perforation without evidence of malignancy.

Discussion: Axial torsion is a rare complication of MD with clinical presentation mimicking other common intra-abdominal pathology. The diagnosis is usually made intraoperatively, even with the

*Corresponding author: E-mail: hianee92@gmail.com;

modern diagnostic methods currently available. Factors associated with higher risk of complications include patient at extremes of age or immunosuppressed, presence of anatomic risk factors such as length of more than two cm, palpable abnormality and presence of fibrous band. Current recommendation suggests excision for all symptomatic MD and asymptomatic MD found during abdominal exploration with risk factors of developing complications. It is important to include complicated MD in our differential diagnosis for patient with such presentation in order to identify and manage accordingly.

Keywords: Meckel's diverticulum (MD); perforated MD; axial torsion of MD.

1. INTRODUCTION

Meckel's diverticulum (MD) was described by a German Anatomist, Johann Friedrich Meckel in the year 1809 [1]. It is the commonest congenital anomaly of the gastrointestinal tract due to incomplete obliteration of the proximal portion of the vitellointestinal duct during the fifth to seventh week of fetal development. Failure of obliteration of the whole tract will result in an umbilical fecal fistula while proximal ductal closure will lead to an umbilical sinus and distal closure will lead to Meckel's diverticulum [2]. The mesodiverticular band connecting to the umbilical ligament used to function as the developmental viteline arteries [3]. MD is usually found on the anti-mesenteric border of ileum, in 90% of cases located up to 90 cm from the ileocaecal valve. The "rule of two" classically used to describe the features of MD: 2% of the population with male to female ratio 2:1, locating two feet from the ileocaecal valve and can be 2 inches in length; and 2-4% of patients tend to develop complication and often occurs at two years of age. It is usually lined by two different types of mucosae which are the native intestinal mucosa and a heterotopic mucosa commonly gastric or pancreatic mucosa [4,5].

Of all Meckel's diverticulum, majority are asymptomatic while only 4% present with complications such as intestinal obstruction (36.5%), intussusception (13.7%), inflammation (12.7%), perforation (7.3%), haemorrhage (11.8%) and tumour (3.2%) [3]. Axial torsion with gangrenous Meckel's diverticulum is a rare complication and we hereby present a case of strangulated Meckel's diverticulum with ischemic perforation secondary to axial torsion.

2. CASE PRESENTATION

A 25-year-old Malay male, who was previously well with no past surgical history presented with central abdominal pain for 2 days associated with 4 episodes of vomiting and fever. On examination, he was septic and tachycardic,

abdominal examination showed tenderness over lower abdominal region with guarding with intact hernial orifices were intact and normal male genitalia. Blood investigation showed leucocytosis of 21.5 with a CRP of 220. Abdominal and chest radiographs showed a gas filled pouch at the right upper part of the abdomen with no pneumoperitoneum.

We proceeded for a laparotomy and intraoperatively there was a long strangulated gangrenous narrow base Meckel's diverticulum at 40cm proximal to the ileocecal junction with ischemic perforation and purulent peritonitis. The Meckel's diverticulum was twisted on its base with a fibrous band connecting to the anterior abdominal wall. We performed a wedge resection of the Meckel's diverticulum and primary repair of the small bowel along with peritoneal lavage. Patient recovered well and was discharged home at day 7 post surgery. The histopathological report of the specimen was consistent with perforated ischemic bowel with no evidence of ectopic mucosa or malignancy.

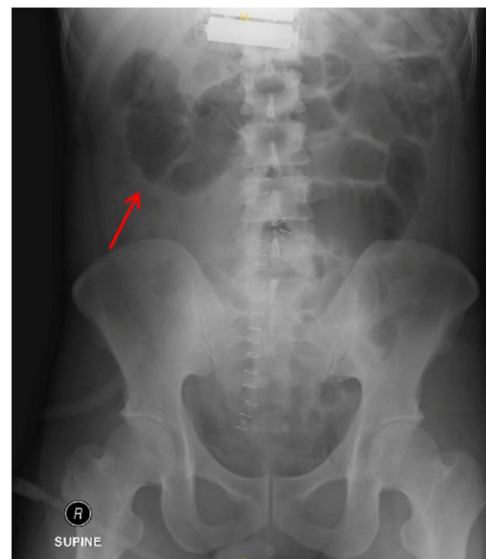


Image 1. Abdominal X-ray revealed a gas filled segment of bowel at the right upper part of abdomen. (Red arrow)

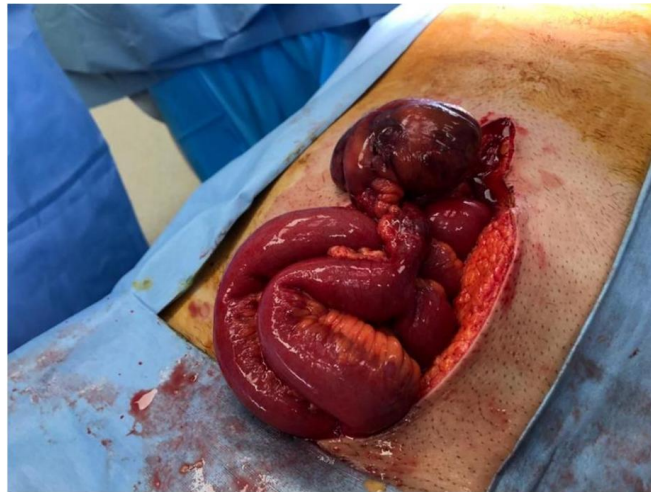

Image 2. Intraoperative finding of a strangulated Meckels diverticulum secondary to axial torsion on its base with purulent peritonitis

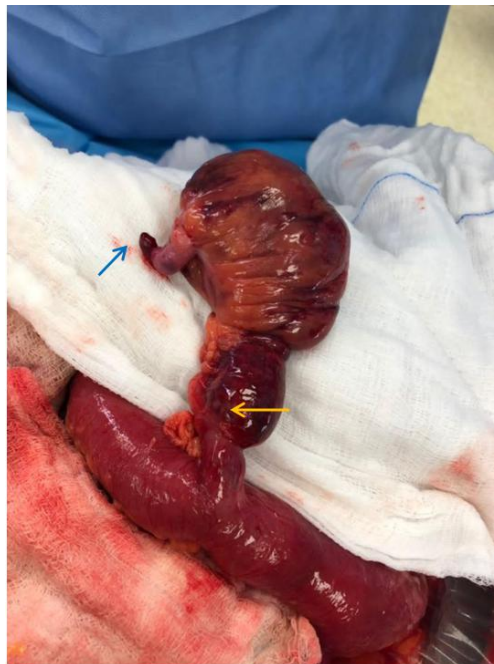

Image 3. Meckel's diverticulum with mesodiverticular band (blue arrow) and narrow base (yellow arrow)

3. DISCUSSION

This case demonstrated an unusual case of axial torsion of MD. Based on the available literature, there are several risk factors, primary neoplasm of MD with both malignant and benign histology is associated with increased risk. With a larger size of the MD, it will lead to potential complications such as intussusception with the tumour as a lead point, mechanical bowel obstruction, volvulus and axial torsion. However,

it is rare with only less than 1% of the incidence [6]. The presence of fibrous vitelline band connecting to the anterior abdominal wall is also a risk factor for torsion of MD, especially with longer length of band and narrower base [4].

The commonest presentation with such condition is always abdominal pain with preoperative diagnosis including appendicitis, small bowel obstruction, cholecystitis or diverticulitis [5]. In addition, the mobility and variation of MD has

made radiological imaging diagnosis very difficult. Therefore, most of the time, patients who are symptomatic will be posted for surgical exploration. Abdominal radiographs are usually normal or may show ileus, pneumoperitoneum or less commonly a gas filled diverticula being mistaken as gall bladder or intussusception segment of bowel [3]. Our case demonstrated a gas filled pouch over the right side of the abdomen on abdominal radiograph. Abdominal ultrasonography is useful in excluding intussusception but with limitations for other complications of MD. Computed tomographic (CT) scans can be misleading as well with reported cases of torted MD reported as cystic mass in the abdomen and pelvis [7].

Based on previous cases reported, intraoperative findings include torsion, ischemia, haemorrhagic or perforation with purulent peritonitis. The greater degree of torsion signifies a worse vascular compromise to the MD and leading to infarction and ischemic perforation with high morbidity which happened in our case [8].

The management for symptomatic MD has been surgical resection and wedge resection is the commonly performed or alternatively resection of the MD segment of small bowel with primary anastomosis [7,9]. For asymptomatic MD discovered during abdominal exploration, current recommendation suggest excision of MD for those patients who are less than 50 year old and has anatomic risk factors such as length of more than 2cm, palpable abnormality, presence of fibrous bands as these are associated with higher risk of complication [10]. In this case, our patient was a young gentleman who presented with an acute abdomen that required surgical intervention and his MD was more than 2cm with a narrow base and with presence of mesodiverticular band. All these are high risk features for complications of MD. Hence, we would recommend excision of MD for all of those with length of more than 2cm with narrow base and presence of mesodiverticular band if found on an abdominal exploration to avoid complications arising in the future.

4. CONCLUSION

This case report demonstrates a patient with axial torsion of MD leading to ischemic perforation. Even with modern imaging techniques, this uncommon condition has most diagnoses made intraoperatively. The major risk factors for such complication includes large size

of MD, longer length with narrow base and presence of mesodiverticular band. It is important for clinicians to be vigilant about MD and its complications to prevent mismanagement.

CONSENT

As per international standard or university standard, patient(s) written consent has been collected and preserved by the author(s).

ETHICAL APPROVAL

As per international standard or university standard written ethical approval has been collected and preserved by the author(s).

COMPETING INTERESTS

Authors have declared that no competing interests exist.

REFERENCES

1. An J, Zabbo CP. Meckel diverticulum. 2023 Jan 30. In: StatPearls [Internet]. Treasure Island (FL): StatPearls Publishing; Jan 2023. PMID: 29763135
2. Lequet J, Menahem B, Alves A, Fohlen A, Mulliri A. Meckel's diverticulum in the adult. *J Visc Surg.* Sep 2017;154(4): 253-259. DOI: 10.1016/j.jviscsurg.2017.06.006 Epub 2017 Jul 9. PMID: 28698005
3. Hansen CC, Søreide K. Systematic review of epidemiology, presentation and management of Meckel's diverticulum in the 21st century. *Medicine (Baltimore).* Aug 2018;97(35):e12154. DOI: 10.1097/MD.00000000000012154 PMID: 30170459 PMCID: PMC6392637
4. Nagata H, Nishizawa H, Mashima S, et al. Axial torsion of Meckel's diverticulum causing acute peritonitis in the first trimester of pregnancy: A case report. *Surg Case Rep* 2019;5:190. Available: <https://doi.org/10.1186/s40792-019-0754-y>
5. Hadeed AA, Azar RR, Azar NN, Benninger B. Meckel's diverticulum complicated by axial torsion and gangrene. *J Surg Case Rep.* Mar 1 2015;2015(3):rjv008. DOI: 10.1093/jscr/rjv008 PMID: 25733669 PMCID: PMC4345285

6. Seth A, Seth J. Axial torsion as a rare and unusual complication of a Meckel's diverticulum: A case report and review of the literature. *J Med Case Reports*. 2011;5: 118.
Available:<https://doi.org/10.1186/1752-1947-5-118>
7. Ahmed M, Elkahly M, Gorski T, Mahmoud A, Essien F. Meckel's Diverticulum Strangulation. *Cureus*. May 3 2021;13(5): e14817.
DOI: 10.7759/cureus.14817
PMID: 34094771
PMCID: PMC8171988
8. Blouhos K, Boulas KA, Tsalis K, Baretas N, Paraskeva A, Kariotis I, Keskinis C, Hatzigeorgiadis A. Meckel's Diverticulum in Adults: Surgical Concerns. *Front Surg*. Sep 3 2018;5:55.
DOI: 10.3389/fsurg.2018.00055
PMID: 30234126
PMCID: PMC6129587
9. AlShareef B, Khudari O. Perforated mesenteric Meckel's diverticulum: Case report. *Int J Surg Case Rep*. Feb 2021;79:271-274.
DOI: 10.1016/j.ijscr.2021.01.027
Epub 2021 Jan 15
PMID: 33486309
PMCID: PMC7829111
10. Park JJ, Wolff BG, Tollefson MK, Walsh EE, Larson DR. Meckel diverticulum: the Mayo Clinic experience with 1476 patients (1950-2002). *Ann Surg*. Mar 2005;241(3): 529-33.
DOI:10.1097/01.sla.0000154270.14308.5f.
PMID: 15729078
PMCID: PMC1356994

© 2023 Heng et al.; This is an Open Access article distributed under the terms of the Creative Commons Attribution License (<http://creativecommons.org/licenses/by/4.0>), which permits unrestricted use, distribution, and reproduction in any medium, provided the original work is properly cited.

Peer-review history:

The peer review history for this paper can be accessed here:
<https://www.sdiarticle5.com/review-history/104137>