



# Intrathoracic Schwannoma with Venous Return to Vena Azygos: A Case Report

Mehmet Ozgel<sup>1\*</sup>

<sup>1</sup>Malatya Training and Research Hospital, Turkey.

## Author's contribution

The sole author designed, analysed, interpreted and prepared the manuscript.

## Article Information

### Editor(s):

(1) Dr. Jose Francisco de Sales Chagas, Professor, Sao Leopoldo Mandic Medical School, Brasil.

### Reviewers:

(1) Ibrahim Mohammed, Usmanu Danfodiyo University Sokoto, Nigeria.

(2) Manas Bajpai, NIMS Dental College, India.

(3) Božo Krušlin, University of Zagreb, Croatia.

Complete Peer review History: <http://www.sdiarticle4.com/review-history/53201>

Case Study

Received 15 October 2019

Accepted 17 December 2019

Published 26 December 2019

## ABSTRACT

**Aims:** Schwannoma is a neurogenic tumour, originating from the nerve sheaths may either be malign or benign. In this case, was presented a giant mass and its an abnormal vascular structure.

**Presentation:** In this case, the location of the big mass was also the posterior sulcus. The mass has been dissected extrapleural from the thoracic wall by a posterolateral thoracotomy. The venous return was detected to be towards to the azygos vein.

**Discussion:** When excising a resectable giant schwannoma mass, the possibility of abnormal vessels or arteries should be kept in mind.

**Keywords:** Schwannoma; posterior mediastinum; vena azygos.

## 1. INTRODUCTION

An intrathoracic neurogenic tumour originating from the chest wall is a rare condition. It is difficult to make an accurate preoperative diagnosis [1]. Neurogenic tumours may develop from the sympathetic chain, the intercostal nerve

sheath or the nerve roots [2-3]. It has a variety of clinical and histological features and generally asymptomatic at onset. When its compression effect begins, it starts being to be symptomatic, and this course of the disease takes a long time [3]. Sometimes it can cause spontaneous bleeding from the mass and is very rare [4].

\*Corresponding author: E-mail: [mozgel44@yahoo.com](mailto:mozgel44@yahoo.com);

Therefore it is crucial to know that vascularity of mass. The arterial and venous blood flow anatomy of the mass can have some variations. [4]. In our case, we report a different unusual venous return of a schwannoma.

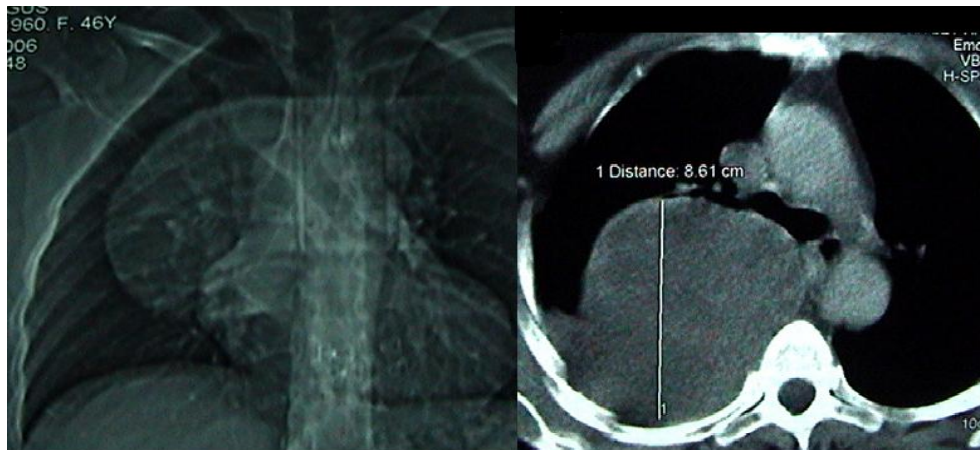
## 2. CASE

A 46-year-old woman patient, whose labouring with animal-breeding suffered from back pain at rest. Facial cyanosis, dyspnea and difficulty to swallow have begun to occur for the last one year progressively. In the last two months, her complaints became unbearable. Physical examination showed dullness on percussion and decrease of breath sounds in the right hemithorax. Chest radiogram showed a hyperdense mass in the right hemithorax. Thoracic computed tomography revealed a large, well-circumscribed lesion that causing the carina to move to left, and under pressuring the right main bronchus and causing atelectasis of upper

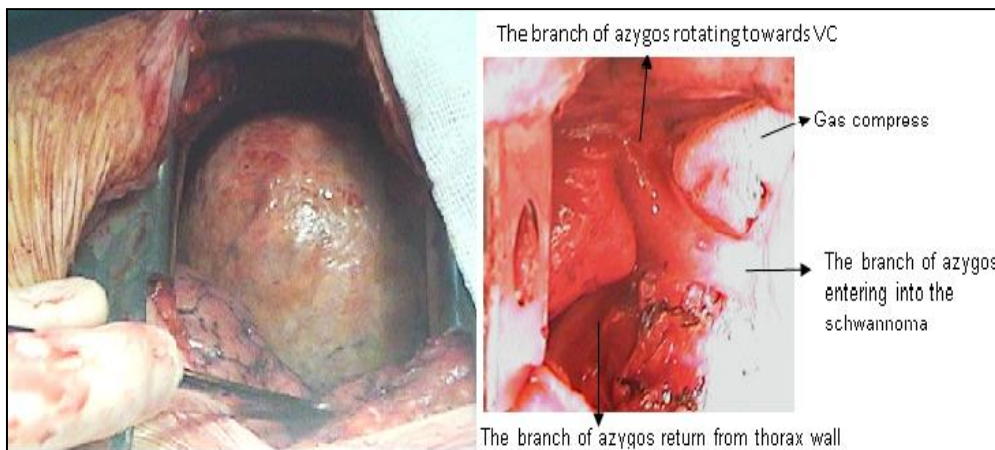
and middle lobe. Also, it has a heterogeneous density. (Fig. 1). A right posterolateral thoracotomy was performed. Passive atelectasis was detected on the upper and lower lobes depending on the extra parenchymal located mass. Three intercostal arteries were entering into the mass and a large vein drained to vena azygos from the mass was detected (Fig. 2). The accessory veins and arteries were double ligated and cut. The mass was excised (Fig. 3). One chest tube is inserted. The patient was discharged on the fifth postoperative day.

Microscopically spindle cell proliferation with palisading of nuclei (Fig. 4.a,b,c) besides the multilocular cyst formations (Fig. 4-d) were observed. It was diagnosed as "benign schwannoma" with the positive staining of S-100 protein immunohistochemically (Fig. 4-e).

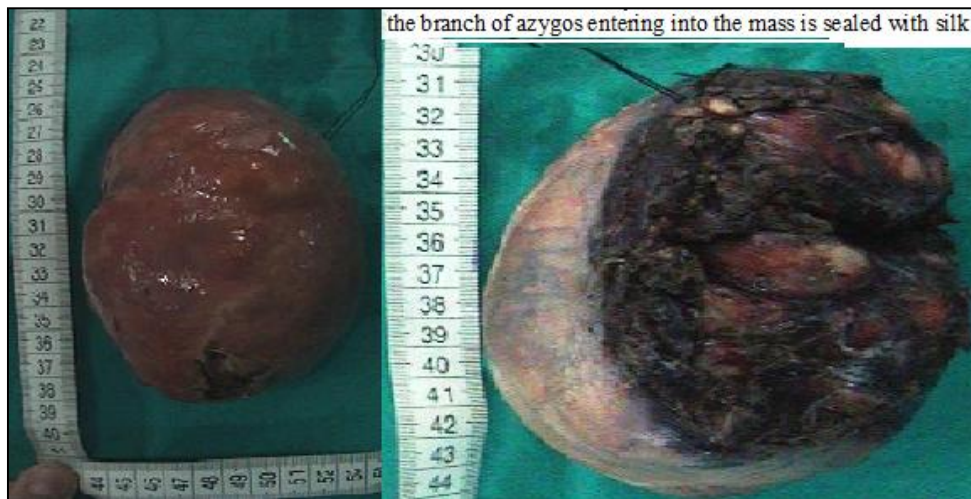The patient is still in our follow-up without any complaints for two years.



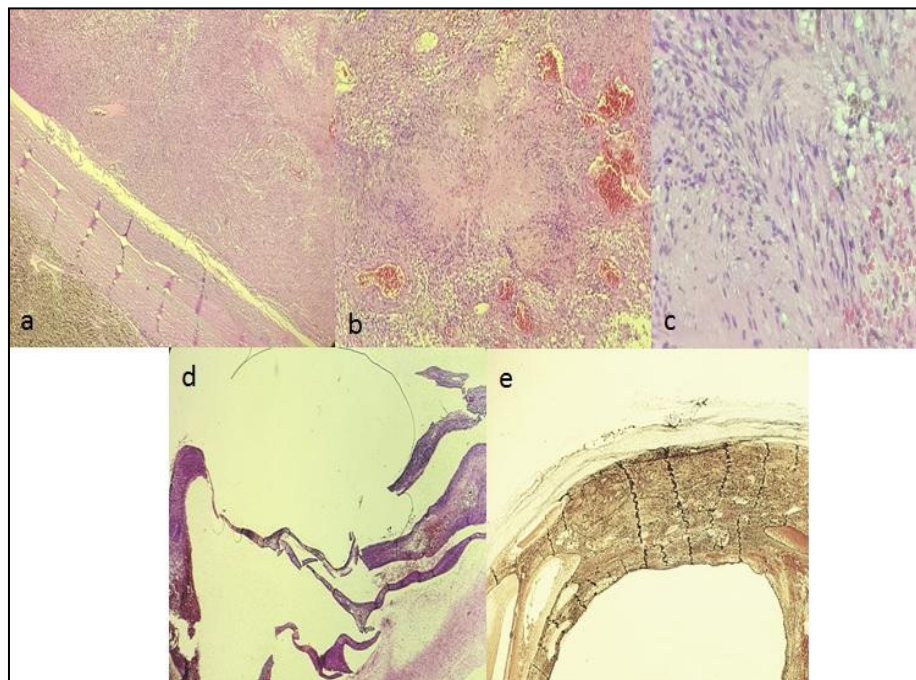
**Fig. 1. CT scan of the upper chest showing a mass in the right lung**



**Fig. 2. Posterior located mass and accessory vein entering into the schwannoma**



**Fig. 3. Anterior and posterior face of the mass**



**Fig. 4. (a). Spindle cell proliferation is seen in the upper right side, anthracosis in the lower left, and fibrous tissue separating them (H&EX40). (b). Palisading of nuclei is seen better in higher power image (H&EX100). (c). A closer view of the palisading nuclei (H&EX400). (d). Multilocular cyst formation is seen (H&EX40), (e). Strong S-100 protein immunoreactivity (H&EX40)**

### 3. DISCUSSION

Most of the schwannomas (90%) originated from the nerve sheath are benign [5]. Schwannoma is common in the head, neck, oral cavity, retroperitoneum, joints and especially in the thorax. Briefly, it can be seen anywhere with nerve sheath. While 60% of the neurogenic tumours are asymptomatic, some of them may cause symptoms such as chest pain, Horner's

syndrome, husky voice and the symptoms related with the vertebra [6].

The nerve sheath tumours appear more frequently on adults and women with the ratio of 73–83% whereas the tumours from the nerve cells more frequently appear on men [7-8].

Schwannoma is generally solitary tumour. It is seen around, well-circumscribed, and

encapsulated in thoracic computed tomography and x-ray. The tissue density varies according to Anthony A and Anthony B contents of the cells [9]. Preoperative diagnosis is very difficult. The fine needle aspiration is rarely successful because of the limited cellularity of these neoplasms. So the diagnose and treatment are with a radical surgical excision in giant schwannoma. Small tumours are often removed using video thoracoscopy [10].

When a thoracic computed tomography angiogram for schwannoma was taken, it can be seen that its vascular structure comes from very different regions, and aberrant formations of those vascular structures can be observed [11]. In the study made by Berlin O, et al. the feeding artery of the nerve affected and the artery connection of the proximal and distal ends of the tumours were revealed in 2 patients, and it was shown that the venous return in the patients was towards the vein following the nerve [12]. In our case, A large vein drained to vena azygos from the mass and three intercostals arteries entering into the mass has been noticed at the operation instantly.

Both schwannomas and neurofibromas, which are neural sheath tumors, may show signs of degeneration such as bleeding, cyst formation, necrosis or calcification due to slow growth. These features are more common in schwannomas than neurofibromas. Immunohistochemically, schwannoma is positive for S-100, Leu-7 and Myelin basic protein confirming its neural origin [13]. Almost all cases of intrathoracic neurogenic tumours were benign. In a study of 60 patients by Yamaguchi M et al., only one patient was diagnosed as malignant schwannoma [3].

#### 4. CONCLUSION

Posterolateral thoracotomy should be performed, if the diameter of schwannoma bigger than 6 cm. Complete removal of the schwannoma by posterolateral thoracotomy provides a full treatment of the patient. But it should be kept in mind, in the giant intrathoracic masses normal feeding arteries and draining veins may be unusual.

#### CONSENT

As per international standard or university standard, patient's consent has been collected and preserved by the authors.

#### ETHICAL APPROVAL

As per international standard written ethical approval has been collected and preserved by the author(s).

#### COMPETING INTERESTS

Author has declared that no competing interests exist.

#### REFERENCES

1. Athanassiadi K, Kalavrouziotis G, Rondogianni D, Loutsidis A, Hatzimichalis A, Bellenis I. Primary chest wall tumors: early and long term results of surgical treatment. *Eur J Cardiothorac Surg.* 2001; 19:589-93.
2. McClenathan JH, Bloom RJ. Peripheral tumors of the intercostal nerves. *Ann Thorac Surg.* 2004;78:713-4.
3. Yamaguchi M, Yoshino I, Fukuyama S, Osoegawa A, Kameyama T, Tagawa T, Maehara Y. Surgical treatment of neurogenic tumors of the chest. *Ann Thorac Cardiovasc Surg.* 2004;10(3):148-51.
4. Yazicioglu A, Yekeler E, Özyaydin E, Karaoglanoglu N. Intrathoracic schwannoma presented with hemothorax. *J Clin Anal Med.* 2016;7(2):99-101.
5. Reed JC, Hallett KK, Feigin DS. Neural tumors of the thorax: subject review from the AFIP. *Radiology* 1978;126:9-17.
6. Arapis C, Gossot DD, Arper L, Mazel C, Grunenwald D. Thoracoscopic removal of neurogenic mediastinal tumors. *Surg Endosc.* 2004;18:1380-1383.
7. Topcu S, Alper A, Gulhan E, Kocyigit O, Tastede I, Cetin G. Neurogenic tumours of the mediastinum: A report of 60 cases. *Can Respir J.* 2000;7(3):261-265.
8. Ribet ME, Cardot GR. Neurogenic tumors of the thorax. *Ann of Thoracic Surgery.* 1994;58(4):1091-1095.
9. Lee JY, Lee KS, Han J, Yoon HK, Kim TS, et al. Spectrum of neurogenic tumors in the thorax: CT and pathologic findings. *J Comput Assist Tomogr.* 1999;23(3):399-406.
10. Lochowski MP, Brzeziński D, Kozak J. Videothoracoscopy in the treatment of benign neurogenic tumours of the posterior mediastinum. *Wideochir Inne Tech Maloinwazyjne.* 2014;9(3):315-318.



11. Aydemir B, Çelik S, Okay T, Doğusoy I. Intrathoracic giant solitary fibrous tumor. Am J Case Rep. 2013;14:91–93.
12. Berlin O, Stener B, Lindahi S, Irstam L, Lodding P. Vascularization of peripheral neurilemmomas: angiographic, computed tomographic, and histologic studies. Skeletal Radiology. 1986;15(4):275-283.
13. Beaman FD, Kransdorf MJ, Menke DM. Schwannoma: Radiologic pathologic correlation. Radiographics. 2004;24:1477-81.

© 2019 Ozgel; This is an Open Access article distributed under the terms of the Creative Commons Attribution License (<http://creativecommons.org/licenses/by/4.0>), which permits unrestricted use, distribution, and reproduction in any medium, provided the original work is properly cited.

*Peer-review history:*

*The peer review history for this paper can be accessed here:*  
<http://www.sdiarticle4.com/review-history/53201>